applied sciences

MDPI

Review

Diagnostic Approaches to Total Knee Arthroplasty Loosening: From Conventional Imaging to Modern Techniques

Robert Karpiński [1,2,*], Aleksandra Prus [3,*], Przemysław Krakowski [4,5], Magdalena Paśnikowska-Łukaszuk [3] and Kamil Jonak [3]

[1] Department of Machine Design and Mechatronics, Faculty of Mechanical Engineering, Lublin University of Technology, 20-618 Lublin, Poland
[2] Institute of Medical Sciences, Faculty of Medicine, The John Paul II Catholic University of Lublin, 20-708 Lublin, Poland
[3] Department of Technical Computer Science, Faculty of Mathematics and Information Technology, Lublin University of Technology, 20-618 Lublin, Poland
[4] Department of Trauma Surgery and Emergency Medicine, Medical University, 20-059 Lublin, Poland
[5] Orthopaedic and Sports Traumatology Department, Carolina Medical Center, 02-757 Warsaw, Poland
* Correspondence: r.karpinski@pollub.pl (R.K.); a.prus@pollub.pl (A.P.)

Abstract

Osteoarthritis (OA) is a severe and progressive joint disease that usually affects elderly people. The consequence of this disease in its advanced stage is the need for total knee arthroplasty (TKA). Over the years, there has been a constant increase in the number of TKA procedures, with a predicted increase to 1.26 million procedures by 2030. Diagnostics are based on conventional radiography, although advanced techniques such as radiostereometry, SPECT/CT and PET/CT, which enable early detection of micromigration, are gaining increasing recognition. Vibroarthrography (VAG) is a proposed supplement to diagnostics, enabling the assessment of the characteristics of vibrations and friction of joint surfaces, thus supporting the process of early detection of endoprosthesis instability. The combination of conventional and alternative diagnostic methods, including vibroarthrography, may improve the detection of early TKA loosening. This may also result in increased implant durability. The aim of this article is to review the current state of knowledge on the classification and analysis of endoprosthesis loosening mechanisms. In addition, classic and modern methods of detecting and monitoring loosening are discussed, with particular emphasis on vibroarthrography as a potential tool for early diagnosis.

Keywords: total knee arthroplasty; vibroarthrography; osteoarthritis; endoprosthesis loosening; aseptic loosening; septic loosening; diagnostic imaging

Check for updates

Academic Editors: Thomas Lindner and Maria Pia Ferraz

Received: 18 October 2025
Revised: 29 December 2025
Accepted: 30 December 2025
Published: 31 December 2025

Copyright: © 2025 by the authors. Licensee MDPI, Basel, Switzerland. This article is an open access article distributed under the terms and conditions of the Creative Commons Attribution (CC BY) license.

1. Introduction

Total knee arthroplasty (TKA) is one of the most effective and commonly performed surgical procedures in the treatment of knee osteoarthritis (OA). Patients' quality of life improves significantly after the TKA by reducing pain and restoring functional capacity [1]. The increase in demand for total knee arthroplasty is associated with an ageing population and, consequently, an increase in the number of patients suffering from OA. It is estimated that by 2040, the number of people affected by osteoarthritis could reach 78.4 million [2]. The United States forecasts growing demand for TKA, as it is predicted that by 2030, 50% of the "baby boomer" population will suffer from arthritis [3].

Although the original purpose of TKA was to treat osteoarthritis, it is now also used in rheumatoid arthritis, periarticular tumours and osteonecrosis [4–8]. Despite its high

efficacy, the procedure is associated with a risk of complications, the most serious of which is loosening of the endoprosthesis components, resulting from mechanical, biological, surgical and patient-dependent factors [9,10]. Diagnosis of loosening includes CT, radiography, SPECT/CT scintigraphy and artificial intelligence-based methods, which are characterised by high sensitivity and specificity [11,12]. A promising technique for assessing TKA stability is vibroarthrography, which, based on acoustic parameters, allows effective differentiation between stable and loose endoprostheses and can complement classical imaging methods [13].

The aim of this article is to present a comprehensive insight into diagnostic modalities used in detecting and monitoring of total joint endoprosthesis loosening.

2. Materials and Methods

A narrative-style literature survey was performed to identify key studies on diagnosing loosening of total knee arthroplasty (TKA) implants. A literature search was conducted in the PubMed database. The review included original research (prospective and retrospective clinical studies) and experimental investigations (biomechanical laboratory studies), as well as validation studies of imaging or diagnostic methods and existing review articles with clearly described methods. Inclusion criteria focused on full-text articles in English involving adult human subjects or relevant mechanical models. Studies were excluded if they were conference abstracts without full text, case reports, or lacked sufficient methodological detail or relevant data. These criteria ensured that included literature provided reliable and applicable information on TKA implant loosening.

Studies evaluating various diagnostic modalities for both aseptic and septic loosening were considered, including conventional imaging (radiography, CT, MRI), nuclear medicine techniques (SPECT/CT, PET/CT), radiostereometric analysis (RSA), and vibroarthrography, among others. Comparisons of interest included different imaging techniques (for example, CT vs. SPECT/CT or advanced MRI sequences vs. conventional MRI) and contrasts between stable and loose implants, in order to identify factors associated with loosening and differences in diagnostic performance. Key outcomes of interest were diagnostic accuracy metrics (sensitivity, specificity, accuracy), implant migration or micromotion parameters, indicators of mechanical stability, and mechanistic insights into loosening.

The findings were then organised thematically according to diagnostic modality. For example, information on conventional and advanced imaging (plain radiography, CT, MRI, nuclear scans), functional or biomechanical assessments (gait analysis, implant vibration/accelerometry tests, etc.), and laboratory or biomarker analyses (serologic or synovial markers, bone turnover markers) were each grouped together. This thematic grouping reflects the narrative approach and helps the reader follow different lines of evidence. A narrative review format was chosen because implant-loosening diagnosis is a heterogeneous field with many methods; this format allows integration of diverse evidence and expert perspectives. By avoiding the rigid structure of a systematic review, the narrative synthesis provides a holistic overview of the state of the art in TKA loosening diagnostics, highlighting strengths and limitations of each modality within a coherent framework.

3. Diagnosis of Endoprosthesis Loosening—Conventional and Alternative Methods

Currently, imaging, laboratory tests, biomechanical tests and VAG can be used for the diagnosis of joint loosening. These methods were selected due to their ability to provide a comprehensive assessment of the condition of the knee joint endoprosthesis. Imaging tests provide basic structural information, while laboratory tests allow differentiation between aseptic and septic loosening, which is crucial for further therapeutic decisions. Biome-

chanical methods allow for the extension of diagnostics to include the assessment of the function and stability of the endoprosthesis in dynamic conditions, which remain invisible in classic static imaging. Vibroarthrography, on the other hand, as a modern and sensitive tool supporting classic diagnostic methods, enables early detection of microinstability and friction changes. The combination of these methods allows for a precise and comprehensive assessment of loosening.

3.1. Imaging-Based Diagnostic Methods

One of the main reasons for revision after TKA is loosening of the knee joint endoprosthesis, which is why detailed imaging diagnostics are required [14]. The first step in diagnosing suspected endoprosthesis loosening is to use radiographs, which can detect component migration, lines of lucidity, or bone defects [14,15]. A definite advantage of this method is its low cost and widespread availability. However, radiography has relatively low sensitivity for detecting early osteolytic changes, although specificity remains high in cases of advanced implant loosening [16]. Vessely et al. [17] demonstrated that standard radiography is insufficient for diagnosing early osteolytic changes within knee joint endoprostheses. Therefore, radiography should be supplemented with advanced examinations in cases of inconclusive clinical results [14].

In the anatomical assessment of the bone-implant interface, CT is a useful imaging method due to its high spatial resolution. The use of CT allows imaging of component migration, osteolysis and fusion defects [18]. However, traditional CT has limitations related to metal artefacts originating from implant components, which is why in recent years the focus has been on developing artefact reduction techniques, resulting in a significant improvement in the ACC (accuracy) of detecting loosening of knee joint endoprostheses [18]. In the study by Zhang et al. [18], the O-MAR (Orthopaedic Metal Artefact Reduction) algorithm was evaluated in orthopaedic imaging and a significant reduction in artefact visibility in 2D and 3D images was found. The application of the O-MAR algorithm improved the bone-prosthesis interface visibility index from 34.3% (Non-O-MAR) to 66.7% (O-MAR). As a result, significantly better visibility of periprosthetic structures was achieved, which also contributed to easier identification of osteolysis foci.

Jeong et al. [19] conducted clinical and phantom studies using the MAR (Metal Artefact Reduction) reduction algorithm, which showed that the use of this algorithm reduces metal artefacts in CT, which has a positive effect on the diagnosis of patients with severe metal artefacts.

In their review, Kohyama et al. [20] compared artefact reduction techniques, presenting specific values. In the two parameters analysed, the use of the DECT (Dual—Energy Computed Tomography) method reduced the number of artefacts by approximately 33% and 8%, while the MAR technique reduced them by as much as ~56% and ~71%. However, combining DECT and MAR techniques resulted in a reduction of ~76% in both measures, confirming the benefits of combining spectral imaging and post-processing technologies.

In turn, Midthun et al. [21] used a combination of MAR with modified acquisition parameters and UHR (Ultra High Resolution), which had a positive effect on artefact reduction, thereby improving CT image quality. This has a significant impact on the assessment of small periprosthetic bone defects.

Shim et al. [22] analysed reconstructed images using FBP (Filtered Back Projection) and O-MAR in patients with RTSA (Reverse Total Shoulder Arthroplasty). It was shown that the use of the O-MAR algorithm contributed to the reduction in artefacts and noise in the form of metallic streaks. However, the authors emphasise that the use of this algorithm

may result in the appearance of artefact-like phenomena or blurring of cortical details, which should be taken into account when interpreting the image.

Another imaging method is MRI (magnetic resonance imaging), which for many years was not used in the diagnosis of endoprosthesis loosening due to significant amounts of metallic artefacts hindering the assessment of structures around the implant [23]. However, the development of sequences that reduce artefacts, such as MAVRIC (Multi-Acquisition Variable-Resonance Imaging Combination) and SEMAC (Slice Encoding for Metal Artefact Correction), has significantly contributed to improving the quality of this imaging technique [24].

Koch et al. [24] developed the MAVRIC and SEMAC hybrid technique, achieving very high quality clinical images. The synthesis of these two sequences reduced signal distortion and elongated streaks, resulting in higher quality visualisation of both bone structures and the soft tissues surrounding the implant. Hayter et al. [25] compared MAVRIC and FSE (Fast Spin-Echo) techniques. Using the MAVRIC technique, much better visualisation of the synovial membrane, periprosthetic bone, and supraspinatus tendon was obtained compared to FSE. Only MAVRIC images showed synovial inflammation and supraspinatus tendon rupture. Such a marked improvement in image quality has implications for the diagnosis of osteolysis and post-inflammatory complications. Based on their research, Choi et al. [26] confirmed the effectiveness of MAVRIC-SL (Multi-Acquisition Variable-Resonance Image Combination Selective) on a 3T scanner compared to the 2D FSE method. Metallic artefacts were reduced and any abnormalities were more clearly visible.

In the study by Sutter et al. [27], the use of SEMAC in patients with TKA resulted in a significant reduction in artefacts, which improved the image quality of bone structures, tendons and ligaments. The detectability of periprosthetic osteolysis also increased notably. In turn, the study by Khodarahmi et al. [28] used compressed-sensing SEMAC, which resulted in a similar level of artefact reduction compared to the traditional method, but in a much shorter time, which is crucial in clinical practice.

One of the key nuclear tests used in diagnosing complications in patients with TKA is bone scintigraphy using 99mTc-phosphonates. Due to its high sensitivity, this method is widely used in detecting bone disorders and remodelling processes, especially in cases of ambiguous symptoms [29]. Planar bone scintigraphy is an extremely important screening test, mainly in cases of atypical clinical symptoms, due to its high sensitivity of 70–90% in various clinical series [30,31]. However, it should be mentioned that this method has limited specificity due to the possibility of tracer uptake not only in cases of aseptic loosening, but also in inflammatory processes, infections, biomechanical overload, or postoperative bone remodelling, which reduces its diagnostic value as the sole diagnostic tool [32]. In order to improve specificity, triphasic bone scan protocols are used, as well as hybrid nuclear and morphological imaging techniques, which results in improved characteristic uptake patterns and better interpretation of results [32]. Triphasic bone scan is highly sensitive in detecting active infectious and inflammatory processes, but its specificity in distinguishing between these and aseptic loosening is quite low, and therefore insufficient for use as the sole method in diagnosing patients with TKA [29,32,33]. To overcome these limitations and increase specificity in the diagnosis of periprosthetic infection, a combination of leukocyte labelling and bone marrow examination is used, resulting in a higher predictive value in distinguishing infection from aseptic loosening [34–36].

Hybrid SPECT/CT (Single Photon Emission Computed Tomography/Computed Tomography) imaging techniques represent a significant diagnostic breakthrough by integrating SPECT functional data and CT anatomical images, the precision of localising increased uptake and the specificity of diagnoses are increased, resulting in improved identification of localised loosening of components and differentiation of the causes of pain [37].

Data from meta-analyses and systematic reviews show that the sensitivity and specificity values of the SPECT/CT method are ~0.86–0.94% (sensitivity) and ~0.85–90% (specificity) for the detection of aseptic loosening [38]. These results confirm that SPECT/CT is one of the most accurate nuclear methods. Research on the use of SPECT/CT to evaluate individual components of prostheses, as well as attempts to establish numerical thresholds for signal intensity that could reliably indicate the risk of loosening, also deserve special attention, although further clinical validation is required [37,39].

An important diagnostic method is SPECT/CT arthrography, where a contrast agent is administered into the joint and the distribution of the radiotracer is then assessed. Bao et al. [40] achieved a diagnostic accuracy of 97% in a small series using this method due to the direct visualisation of the gap between the cement/bone and the implant. Radionuclide arthrography SPECT/CT can be extremely useful in planning revision surgery, as it provides information about tracer accumulation in the joint while indicating the precise anatomical location on CT [41]. The use of leukocyte scintigraphy combined with bone marrow examination is also a groundbreaking approach, as it increases the diagnostic specificity of infection compared to conventional scintigraphy [42]. Systematic studies and practical considerations indicate the use of a sequential algorithm, which includes the use of planar scintigraphy as a screening test, SPECT/CT in cases of inconclusive results, and leukocyte scintigraphy in cases of suspected infection [36].

Comparative studies of classic scintigraphy and PET/CT (Positron Emission Tomography/Computed Tomography) were also conducted, which showed significantly higher spatial resolution and more precise assessment of bone tissue remodelling with PET/CT; however, due to its limited availability and high costs, it is not the method of first choice [43,44]. Another interesting approach is the synthesis of leukocyte + SPECT/CT protocols, which provide more precise information on the location of periprosthetic infection and improve the detection of PJI [42].

Based on clinical protocols, scintigraphy should be used as a screening or supplementary test when radiography, CT or MRI results are inconclusive, and the decision to revise should be made on the basis of a comprehensive imaging, clinical and microbiological analysis [14,45]. In economic terms, the use of SPECT/CT for the diagnosis of painful TKA may be a cost-effective method in the long term, reducing the number of unnecessary revisions and improving the process of classifying patients for surgical treatment [46]. However, like any method, SPECT/CT also has its limitations. The main limitations include lower spatial resolution compared to CT/MRI, dependence of uptake values on the healing phase and type of implant, limited availability, duration of the examination, and the need for cell labelling in the case of leukocyte scintigraphy [32,47]. Comparative studies and meta-analyses highlight the heterogeneity of nuclear imaging protocols, which significantly hinders comparisons and emphasises the need for their standardisation [32,48].

A summary and comparison of imaging techniques used in the diagnosis of TKA loosening is presented in Table 1.

Table 1. Comparison of imaging methods in the diagnosis of TKA loosening.

Imaging Method	Sensitivity/Specificity	Advantages	Disadvantages	Sources
Radiography	50–70%/70–90%	Preliminary radiological assessment of component location, presence of large radiolucent lines and signs of migration	Low sensitivity in early osteolysis, lack of information on metabolism	[14,17,30]
CT	70–90%/75–90%	Precise assessment of the bone/implant interface, useful in revision planning	Radiation, presence of metallic artefacts	[18,21,38]

Table 1. *Cont.*

Imaging Method	Sensitivity/Specificity	Advantages	Disadvantages	Sources
CT MAR/DECT	80–95%/85–95%	Reduction in metallic artefacts, precise detection of osteolysis and evaluation of the interface	Limited availability, dedicated software required	[18,20,21,38,49,50]
MRI (MAVRIC/SEMAC)	75–90%/80–90%	Precise imaging of soft tissues, no radiation, detection of effusion, synovitis, abscesses, bone marrow changes	High cost, longer examination time, presence of metallic artefacts, although in limited quantities	[25–28,50,51]
Planar bone scintigraphy	70–90%/30–85%	Sensitive screening for metabolic changes and bone remodelling	Low specificity	[29,30,36]
SPECT	80–95%/60–85%	Better location, 3D functional image	No precise anatomical correlation without CT	[29,36]
SPECT/CT	86–94%/85–90%	Differentiation between loosening and non-specific changes, precise localisation of foci of increased uptake, usefulness in planning revision surgery	High cost, limited availability, CT radiation	[38,49,50,52]
Leukocyte scintigraphy	80–91%/80–97%	High specificity, ideal tool for differentiating between aseptic loosening and PJI	Requires a laboratory, time-consuming procedure	[34,36]
PET/CT	90–95%/85–90%	High resolution and quantitative assessment capability, useful in the process of bone remodelling assessment	High cost, limited availability, lack of standardisation	[51,53]

3.2. Contemporary Laboratory Diagnostic Methods for Assessing Knee Endoprosthesis Stability

Excluding PJI plays an important role in the differential diagnosis of knee replacement, due to the different surgical treatment regimens [54]. In addition to imaging techniques, laboratory diagnostics are also crucial. In a first step, screening tests such as ESR and CRP (C-reactive protein) are performed, which have the indispensable advantages of low cost, availability, and information on inflammatory activity in the body, but are characterised by limitations in the form of reduced sensitivity and specificity in the detection of PIJ [55,56]. Therefore, these tests are recommended as a supplement to clinical images and local examination results [57].

In order to improve diagnostic accuracy, synovial inflammatory markers were taken into account, particularly IL-6 in joint fluid, which, based on meta-analyses, were characterised by higher sensitivity and accuracy compared to CRP, ESR, and serum IL-6 [58,59]. In their study, Xie et al. [58] demonstrated high AUC values of ~0.96 for synovial IL-6, which makes this marker particularly useful in the diagnosis of PJI of the knee and hip. Based on the cellular analysis of joint fluid, specifically the number of leukocytes and the percentage of neutrophils, it was shown that, in combination with biochemical markers, this is a key diagnostic parameter that increases the accuracy of diagnosis [55,59].

A routine part of PJI diagnosis is joint fluid aspiration, in which the aspirate undergoes comprehensive biochemical, cytological and biochemical testing [55,60]. Li et al. [60] conducted a meta-analysis which showed that the use of PCR techniques in joint fluid increases the detection rate of pathogens, especially in cases where antibiotic therapy has been previously implemented, while the results vary due to the diversity of methods and the risk of contamination. Modern multiplex PCR panels demonstrate the ability to identify a wide spectrum of microorganisms and promising speed of action, which results in increased effectiveness of antibiotic therapy; however, their limitations include high cost and availability [61,62].

An extremely important supplement to classic tissue and joint fluid cultures is the sonication of removed implants, which involves the mechanical disruption of bacterial biofilm

from the surface of the endoprosthesis, increasing the recovery of microorganisms [63]. In their study, Trampuz et al. [63] developed and validated a sonication protocol in which removed prostheses were placed in a sterile container with liquid, then subjected to ultrasound with specific parameters, followed by culture of the sonicated liquid. A significantly higher sensitivity of 78.5% was achieved compared to classic tissue cultures (60.8%), while maintaining a comparable specificity (98.8% compared to 99.2% for traditional techniques). These results confirm the possibility of using sonication to detect microorganisms hidden in biofilm in situations where classic culture methods fail, especially in patients who have previously undergone antibiotic therapy. Subsequent meta-analyses and technical studies have confirmed that SFC (Sonicate Fluid Culture) testing significantly increases diagnostic sensitivity compared to classical microbiological methods [64–66]. SFC is particularly useful in chronic infections and in cases where biofilm is the main form of microbial survival [64,66]. The effectiveness of sonication is influenced by factors such as the duration and intensity of the ultrasound treatment, the volume of the liquid, as well as the conditions under which the samples are stored and transported [64–66]. In the study by Alvarez Otero et al. [65], an attempt was made to determine the cut-off values (CFU/mL) relevant in the context of PJI, which will reduce false positive results resulting from contamination.

Another laboratory approach is needle or arthroscopic synovial biopsy, which provides material for histopathological and microbiological testing, increasing diagnostic accuracy, especially when fluid results are inconclusive or chronic [67]. Mederake et al. [67] emphasised that technically controlled synovial biopsy increases the probability of identifying inflammation and the presence of neutrophilic infiltrates, which is crucial in differentiating PJI from aseptic loosening. The role of biopsy in cases of negative joint fluid cultures was highlighted. One of the auxiliary criteria in the definition of PJI is the histopathological assessment of the periprosthetic membrane, taking into account, among other things, the number of neutrophils in the field of view, which increases the diagnostic value in combination with serological and microbiological results [55,57,67]. The effectiveness of a biopsy depends on technical factors, such as the number and method of specimen collection, as well as the experience of the diagnostic team, which is directly related to the sensitivity and specificity of this method [67]. In clinical practice, this procedure is particularly considered when complex revision is planned, in situations where the results obtained by other methods are inconclusive [55,67].

One of the most thoroughly researched and promising synovial biomarkers is α-Defensin. It shows high sensitivity and specificity in both laboratory tests and rapid lateral flow tests, and the results are relatively insensitive to prior antibiotic therapy [62,68]. Validation studies and review papers demonstrate the effectiveness of this biomarker as a test confirming PJI; however, its high cost and availability are significant limitations [62,68]. In clinical practice, the leukocyte esterase strip test is often used as a screening test due to its speed of use and low cost, although it has relatively low sensitivity and specificity compared to comprehensive synovial tests, and therefore mainly serves to support clinical decisions [62]. In addition, D-dimer and other haemostasis markers are considered as a supplement to the diagnostic panel, although further research should be based on the development of interpretation thresholds for PIJ, which is why their use is currently limited [62]. In turn, the combination of sonication and MALDI-TOF technology enables faster identification of microorganisms recovered from implants [69]. Beguiristain et al. [69] demonstrated that this approach significantly reduces the time needed to accurately diagnose the pathogen; however, a limitation is the need to perform culture tests to assess antibiotic sensitivity.

3.3. Biomechanical Methods

The stability of endoprosthesis components and osseointegration depend on the biomechanical load transferred by the knee joint during walking, hence in the case of abnormal gait standards there is an increased risk of aseptic loosening of the endoprosthesis [70]. As mentioned in previous sections, the key cause of revision after TKA is aseptic loosening, which is why clinical, imaging, and biomechanical data must be synthesised to understand the mechanisms responsible for implant failure [71]. Early detection of component migration is possible by RSA (Radiostereometric Analysis) and its variants, such as CT-RSA or dynamic RSA, and the data obtained is often combined with biomechanical gait analysis [72].

In the case of an incorrect load axis in the frontal plane, a concentration of forces is generated on one side of the tibial bearing, resulting in uneven loading and, as a result, leading to gradual migration of the component [73]. As a result of uneven load distribution between the limbs resulting from a shortened support phase or reduced walking speed, there is an increase in cyclically repetitive contact forces, which in theory may accelerate micro-movements of the implant and, as a consequence, lead to degradation of the cement/bone interface bone or bone/implant surface [74]. Any changes in the timing and distribution of joint moments affect changes in the contact force profile in the joint and may contribute to increased loading on the posterior-medial or lateral areas of the tibiofemoral surface, which correlates with the migration patterns of components in radiostereometric analyses [73]. The key factors for assessing mechanical risk that appear in the literature are gait parameters such as walking speed, step length, cadence, maximum knee flexion range, and double support time [73–75]. Parameters such as gait dynamics and kinetic parameters are equally important for diagnosis, as unlike simple static measurements, they provide more precise information about the local load on the joint [74].

Ro et al. [70] developed a musculoskeletal model of TKA, which showed that misalignment in the frontal plane and ligament laxity asymmetry strongly contribute to increased local contact forces during walking, which increases the risk of mechanical overload of the component. Modelling allows for the combination of different implant settings and ligament balance levels, making it possible to identify the configurations of components most prone to migration.

Based on RSA data and meta-analysis, it was concluded that early migration may predict future aseptic loosening, providing a basis for synthesising these measurements with gait analysis to identify the mechanical cause of migration [71,72]. The data contained in meta-analyses indicate specific migration thresholds and typical directions of translation and rotation that correlate with an increased risk of revision, allowing for testing the relationship between biomechanical gait characteristics and migration trends observed in RSA analyses [71]. Dynamic RSA (dRSA) and CT-RSA methods allow for precise assessment of component kinematics during functional tasks, such as step-up or sit-to-stand, enabling the detection of inducible micromotion, i.e., micro-movements caused by load, which may correlate with specific gait patterns [72]. Validation of the model-based dRSA approach allows for the integration of both biomechanical data and real-time imaging analysis of implant movement, opening up new possibilities for identifying the mechanisms leading to gradual loosening [76,77].

Monitoring load asymmetry and gait variability in everyday conditions is possible using accelerometers, IMUs, and pressure sensors in the sole, which enable the recording of repetitive load standards that may not be visible during laboratory analysis [78]. Analysis of data obtained from wearable devices allows for the identification of progressive changes, such as gradual increase in asymmetry, and combining this data with periodic RSA measurements could enable prediction of component migration before clinical symp-

toms occur [77,79]. The study by Giuntoli et al. [80] describes the use of intraoperative measurement probes in TKA, which provide measurements of the distribution of forces between components and enable the surgeon to optimise the load balance. Additionally, Al-Nasser et al. [81] described the use of an AI-assisted intraoperative sensor to more accurately predict load distributions during surgery.

The integration of gait analysis, electromyography (EMG), in silico modelling and RSA/CT-RSA data is the most comprehensive approach to detecting the mechanical causes of loosening and identifying possible sites for intervention [70–72].

As part of effective research practice in assessing the stability of endoprosthesis components, it is recommended to collect standard gait parameters, perform perioperative measurements using load-sensing to optimise ligament balancing, measure muscle strength and EMG signals, focusing mainly on the quadriceps and hamstrings, and finally, performing cyclic measurements of component migration using RSA/CT-RSA to enable correlation with biomechanical parameters and detect the risk of loosening at an early stage [74,75,80,82–86]. In order to reduce gait asymmetry and improve functional parameters, it is recommended to implement rehabilitation aimed at rebuilding extensor strength and balancing the muscles between the quadriceps and hamstrings, which will effectively reduce adverse cyclic loads on the implant and thus the risk of component migration [83,85,87,88]. However, further randomised studies are needed to compare postoperative care and interventions focused on correcting gait kinematics and muscle balance in order to verify whether these interventions significantly reduce the incidence of aseptic loosening at the population level [71,73].

Currently, available analyses of gait after TKA are based on retrospective studies or have been conducted on relatively small study groups, which means that the long-term correlation between gait parameters and the need for revision is not sufficiently documented [74]. Another important issue is the lack of consistent protocols for combining data from wearable devices, EMG, real-time load measurements, and RSA, which significantly hinders the comparison of results between research centres and the synthesis of scientific evidence [72,79,84,86].

3.4. Vibroarthrography

Due to the difficulties associated with detection of loosening using imaging methods, interest has grown over the years in methods based on recording and analysing dynamic mechanical signals generated by the musculoskeletal system and at the implant–bone interface [89,90]. The answer to these challenges seems to be vibroarthrography, a constantly evolving, non-invasive method involving the recording of vibrations and acoustic emissions (AE) generated by friction, micro-movements and local damage processes in the joint and on the implant surface [89,91–93]. Initially, VAG was used as a tool for assessing the quality of joint surfaces, improving the process of OA diagnosis [91]. However, over time, the concept of VAG began to be extended to other areas of orthopaedics, including the assessment of the quality of endoprostheses [13]. In addition to being non-invasive, other inherent advantages of this method include low cost and rapid signal analysis in clinical conditions [91]. Since VAG recording is performed through the skin using small accelerometers and microphones, this method is completely safe for the patient. A diagram of a typical process of recording and analysing a vibroarthrographic signal is shown in Figure 1.

The biomechanical properties of the implant–bone interface determine the stability of the knee endoprosthesis. As a result of endoprosthesis implantation, bone tissue undergoes remodelling due to new loading conditions, and as a consequence of good integration, the implant retains high stiffness and minimal microkinetics [94]. In the case of interface degradation, for example, as a result of uneven load transfer, micro-movements occur,

which affect the propagation characteristics of vibrations [13]. The problem of microloosening may arise shortly after TKA, although this process does not necessarily have to be associated with any clinical symptoms [95]. The direct cause of their formation is local loss of rigidity in the prosthesis-bone contact zone, leading to microcracks in the bone trabeculae [96]. As a result, the biomechanical transfer of forces from the joint surface to the bone substrate is disrupted, which correlates with the formation of characteristic vibration signals emitted during movement [13].

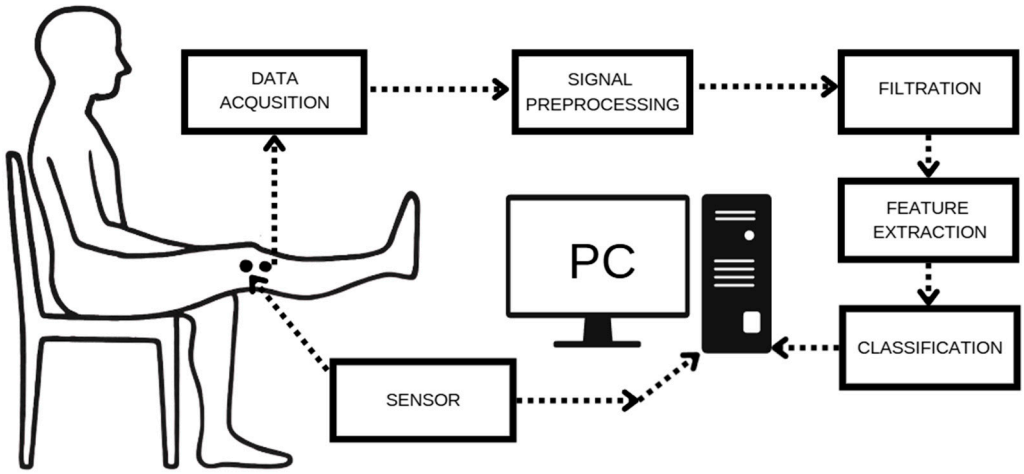

Figure 1. Diagram of a typical process of recording and analysing a vibroarthrographic signal.

In ex vivo studies, Arami et al. [13] performed vibroacoustic measurements using piezoelectric sensors placed near the prosthesis-bone contact zone. As a result of the gradual loosening of the fixing screw, the prostheses were subjected to loosening. As the loosening of the implant progressed, significant changes in the VAG signal characteristics were observed, such as an increase in amplitude or changes in the frequency distribution of vibrations. In the case of a loosened implant, new peaks were observed in the power spectrum, as well as a shift and flattening of existing peaks. A correlation between changes in VAG signal parameters and radiological findings was also demonstrated, confirming the usefulness of this method in the early diagnosis of prosthesis loosening. Authors achieved an accuracy of 92.26%, high sensitivity of 91.67% and specificity of 92.86% using input–output coherence analysis, thus confirming the possibility of differentiating between safe and loose implants. In turn, studies monitoring hip implants using AE have shown that changes in acoustic signals in the form of new frequency modes or changes in the number and energy of AE pulses are directly related to material degradation and operational changes [97,98]. The results obtained are the basis for predicting the adaptation of this methodology to knee implants, after prior methodological adjustment. However, it should be mentioned that these are experimental studies and do not include clinical validation, and the available in vivo data are limited.

The work of Georgiou et al. [99] is one of the few examples of clinical research on the use of VAG in the assessment of hip joint endoprosthesis loosening. During the tests, sensitivity of approximately 80% and specificity of approximately 89% were achieved. The obtained results confirm the usefulness of vibration analysis in clinical conditions; however, there are no similar studies on knee joint endoprostheses. When compared to standard imaging tests, such as SPECT/CT (sensitivity 86–94%, specificity 85–90%), there is a clear need for prospective comparative studies of VAG with established diagnostic methods.

Laboratory analyses suggest that even minor, radiologically invisible changes in cement or implant adhesion may affect changes in vibration propagation modalities, such as reduced coherence or new spectral peaks [13]. Early micro-movements and cement

defects are not visible in conventional X-ray images, which is why the implementation of AE/VAG-based methods can improve the process of early detection of loosening, before clinical symptoms appear [89,90]. Nevertheless, large prospective studies comparing VAG/AE outcomes with surgical assessment should be implemented.

As any method, vibroarthrography also has its limitations. Attempts have been made to use VAG in the diagnosis of endoprosthesis component loosening, but most studies have been conducted in vitro or experimentally, which would require confirmation of the effectiveness of this method in large clinical trials involving patients [13,100,101]. Existing in vivo studies do not provide a sufficient number of randomised and prospective multicentre analyses comparing VAG with recognised diagnostic standards such as conventional radiography, CT, MRI, scintigraphy and surgical outcomes. However, there is a lack of reliable and widely confirmed clinical data in the context of implant loosening detection [91,102].

Another significant limitation is the susceptibility of VAG signals to motion artefacts, friction between the skin and the sensor, ambient noise, and instability in sensor attachment, which makes it difficult to distinguish technical artefacts from pathophysiological signals [12,91]. The type of sensor used, its location and method of attachment have a significant impact on the frequency and amplitude characteristics of the recorded signal [91]. The movements performed by the patient during signal recording, such as their cadence and range between repetitions, affect the variability of the results, which results in variability and limited repeatability, increasing the risk of diagnostic failures [103,104]. Signal quality can be improved by using advanced processing methods such as adaptive filters, segmentation, or time-frequency windows, but there is a lack of standardised preprocessing decisions between clinical centres [12,91].

In existing studies, there is a large discrepancy in research protocols concerning different types of sensors, frequency ranges, sensor locations, the type and range of movement performed during the study, filtration methods, and parameters extracted from the signal, which significantly hinders the comparability of results and repeatable validation of algorithms. Depending on the research team, different descriptive measures and classification criteria are used, which makes it difficult to establish universal threshold values for sensitivity and specificity [105,106]. In the analysis of VAG signals, disruptive factors such as patient weight, soft tissue thickness, implant type and structure, infections, microdamage to the bone bed, the presence of cement or other materials between surfaces should also be taken into account, as they may affect the nature of wave propagation, thus hindering unambiguous signal interpretation [13].

A summary and comparison of diagnostic methods for detecting loosening of knee joint endoprostheses is provided in Table 2.

Table 2. Comparison of diagnostic methods for knee joint endoprosthesis loosening.

Diagnostic Method	Advantages	Limitations	Sources
RTG	availability, low cost, assessment of component migration over time, assessment of osteolytic gap presence	limited sensitivity, lack of information about the condition of soft tissues, influence of metallic artefacts on the interpretation of results	[14–17,107]
CT	high spatial resolution, precision in assessing bone loss and gaps around the implant, possibility of 3D reconstruction	influence of metallic artefacts on the interpretation of results, ionising radiation, limited specificity in differentiating between aseptic loosening and infection	[18,108,109]
MRI	assessment of soft tissues and synovial membrane, imaging capability in the presence of metal, detection of effusion and inflammatory response	high cost, examination time, more difficult accessibility, possibility of limitation due to metallic artefacts	[23,110,111]

Table 2. *Cont.*

Diagnostic Method	Advantages	Limitations	Sources
Bone scintigraphy	high sensitivity to metabolic changes, detection of loosening prior to radiological changes, possible differentiation between infection and aseptic loosening in combination with leukocyte testing	low specificity, radioactive isotropes, limited spatial resolution	[29–32]
SPECT/CT	differentiation of the type of loosening, precise localisation of the area of increased metabolism	high cost, limited availability, radiation	[39,40,42]
Laboratory diagnostics (CRP, ESR, leukocytosis, joint aspirate culture)	essential in differentiating between aseptic loosening and infection, availability, low cost, key microbiological information	requires interpretation in conjunction with imaging, normal inflammatory values in chronic infection, no specificity for aseptic loosening	[58,112]
VAG	non-invasive, no radiation, dynamic assessment during movement, sensitivity to mechanical changes in the implant–bone connection	lack of extensive clinical validation, high sensitivity to motion artefacts and interference, lack of standardisation of measurement protocols and data analysis	[13,89,91,92,100–102]

4. Conclusions and Future Directions

Early joint replacement loosening diagnosis is difficult because the initial changes are usually asymptomatic, and standard imaging methods and laboratory tests may not detect micro-movements at the implant–bone interface, prompting the search for new tools such as SPECT/CT, PET/CT, biomarkers and vibroarthrography. Vibroarthrography, which analyses vibrations generated by joint surfaces, is becoming a promising method for detecting early destabilising changes, although its full clinical implementation requires further standardisation.

Author Contributions: Conceptualization, R.K. and P.K.; methodology, A.P. and R.K.; validation, R.K. and K.J.; formal analysis, R.K., P.K., A.P. and K.J.; investigation, A.P., R.K. and M.P.-Ł.; resources, A.P. and R.K.; data curation, A.P., R.K. and M.P.-Ł.; writing—original draft preparation, A.P., R.K. and P.K.; writing—review and editing, R.K., A.P., P.K., M.P.-Ł. and K.J.; visualisation, R.K. and P.K.; supervision, R.K., P.K. and K.J. All authors have read and agreed to the published version of the manuscript.

Funding: This research received no external funding.

Institutional Review Board Statement: Not applicable.

Informed Consent Statement: Not applicable.

Data Availability Statement: No new data were created or analyzed in this study.

Conflicts of Interest: The authors declare no conflicts of interest.

Abbreviations

ACC: accuracy, AE: acoustic emission, BMD: bone mineral density, CRP: C-reactive protein, CT: computed tomography, DAIR: debridement, antibiotics, and implant retention, DECT: Dual–Energy Computed Tomography, DMARDs: disease–modifying drugs, EPS: extracellular matrix, ESR: erythrocyte sedimentation rate, FBP: Filtered Back Projection, MAR: Metal Artefact Reduction, MAVRIC: Multi-Acquisition Variable-Resonance Imaging Combination, MRI: magnetic resonance imaging, MSIS: Musculoskeletal Infection Society, NGS: Next Generation Sequencing, OA: osteoarthritis, O-MAR: Orthopaedic Metal Artefact Reduction, OPG: osteoprotegerin, PCR: polymerase chain reaction, PET: Positron Emission Tomography, PJI: periprosthetic joint infection, RA: rheumatoid arthritis, RANKL: Receptor Activator of Nuclear Factor κB Ligand, RSA: Radiostereometric Analysis, RTSA Reverse Total Shoulder Arthroplasty, SFC: Sonicate Fluid Culture, SEMAC: Slice Encoding for Metal

Artefact Correction, SPECT: Single Photon Emission Computed Tomography, TKA: total knee arthroplasty, UHR: Ultra-High-Resolution, VAG: vibroarthrography.

References

1. Kim, M.-S.; Kim, J.-J.; Kang, K.-H.; Lee, J.-H.; In, Y. Detection of Prosthetic Loosening in Hip and Knee Arthroplasty Using Machine Learning: A Systematic Review and Meta-Analysis. *Medicina* **2023**, *59*, 782. [CrossRef]
2. Hootman, J.M.; Helmick, C.G.; Barbour, K.E.; Theis, K.A.; Boring, M.A. Updated Projected Prevalence of Self-Reported Doctor-Diagnosed Arthritis and Arthritis-Attributable Activity Limitation Among US Adults, 2015–2040. *Arthritis Rheumatol.* **2016**, *68*, 1582–1587. [CrossRef] [PubMed]
3. Nham, F.H.; Patel, I.; Zalikha, A.K.; El-Othmani, M.M. Epidemiology of Primary and Revision Total Knee Arthroplasty: Analysis of Demographics, Comorbidities and Outcomes from the National Inpatient Sample. *Arthroplasty* **2023**, *5*, 18. [CrossRef] [PubMed]
4. Kerner, P.J.; Clarke, H.D.; Scuderi, G.R. Total Knee Arthroplasty for Rheumatoid Arthritis. *Mod. Rheumatol.* **2003**, *13*, 289–292. [CrossRef]
5. Qiao, Y.; Li, F.; Zhang, L.; Song, X.; Yu, X.; Zhang, H.; Liu, P.; Zhou, S. A Systematic Review and Meta-Analysis Comparing Outcomes Following Total Knee Arthroplasty for Rheumatoid Arthritis versus for Osteoarthritis. *BMC Musculoskelet. Disord.* **2023**, *24*, 484. [CrossRef]
6. Ren, Y.; Yang, Q.; Luo, T.; Lin, J.; Jin, J.; Qian, W.; Weng, X.; Feng, B. Better Clinical Outcome of Total Knee Arthroplasty for Rheumatoid Arthritis with Perioperative Glucocorticoids and Disease-Modifying Anti-Rheumatic Drugs after an Average of 11.4-Year Follow-Up. *J. Orthop. Surg. Res.* **2021**, *16*, 84. [CrossRef]
7. Hernigou, P.; Auregan, J.C.; Dubory, A.; Flouzat-Lachaniette, C.H.; Chevallier, N.; Rouard, H. Subchondral Stem Cell Therapy versus Contralateral Total Knee Arthroplasty for Osteoarthritis Following Secondary Osteonecrosis of the Knee. *Int. Orthop.* **2018**, *42*, 2563–2571. [CrossRef] [PubMed]
8. Houdek, M.T.; Wagner, E.R.; Wilke, B.K.; Wyles, C.C.; Taunton, M.J.; Sim, F.H. Long Term Outcomes of Cemented Endoprosthetic Reconstruction for Periarticular Tumors of the Distal Femur. *Knee* **2016**, *23*, 167–172. [CrossRef]
9. Sharkey, P.F.; Lichstein, P.M.; Shen, C.; Tokarski, A.T.; Parvizi, J. Why Are Total Knee Arthroplasties Failing Today—Has Anything Changed After 10 Years? *J. Arthroplast.* **2014**, *29*, 1774–1778. [CrossRef]
10. Wretenberg, P. Implant Movement Analysis (IMA), A New CT Based Technique for Diagnosis of Aseptic Loosening of Total Knee Arthroplasty. *Orthop. Res. Online J.* **2021**, *8*, 868–872. [CrossRef]
11. Kim, M.-S.; Cho, R.-K.; Yang, S.-C.; Hur, J.-H.; In, Y. Machine Learning for Detecting Total Knee Arthroplasty Implant Loosening on Plain Radiographs. *Bioengineering* **2023**, *10*, 632. [CrossRef] [PubMed]
12. De Tocqueville, S.; Marjin, M.; Ruzek, M. A Review of the Vibration Arthrography Technique Applied to the Knee Diagnostics. *Appl. Sci.* **2021**, *11*, 7337. [CrossRef]
13. Arami, A.; Delaloye, J.-R.; Rouhani, H.; Jolles, B.M.; Aminian, K. Knee Implant Loosening Detection: A Vibration Analysis Investigation. *Ann. Biomed. Eng.* **2018**, *46*, 97–107. [CrossRef]
14. Walker, E.A.; Fox, M.G.; Blankenbaker, D.G.; French, C.N.; Frick, M.A.; Hanna, T.N.; Jawetz, S.T.; Onks, C.; Said, N.; Stensby, J.D.; et al. ACR Appropriateness Criteria® Imaging After Total Knee Arthroplasty: 2023 Update. *J. Am. Coll. Radiol.* **2023**, *20*, S433–S454. [CrossRef]
15. Wautier, D.; Ftaïta, S.; Thienpont, E. Radiolucent Lines around Knee Arthroplasty Components: A Narrative Review. *Acta Orthop. Belg.* **2020**, *86*, 82–94.
16. Palestro, C.J. Radionuclide Imaging of Musculoskeletal Infection: A Review. *J. Nucl. Med.* **2016**, *57*, 1406–1412. [CrossRef] [PubMed]
17. Vessely, M.B.; Frick, M.A.; Oakes, D.; Wenger, D.E.; Berry, D.J. Magnetic Resonance Imaging with Metal Suppression for Evaluation of Periprosthetic Osteolysis After Total Knee Arthroplasty. *J. Arthroplast.* **2006**, *21*, 826–831. [CrossRef]
18. Zhang, K.; Han, Q.; Xu, X.; Jiang, H.; Ma, L.; Zhang, Y.; Yang, K.; Chen, B.; Wang, J. Metal Artifact Reduction of Orthopedics Metal Artifact Reduction Algorithm in Total Hip and Knee Arthroplasty. *Medicine* **2020**, *99*, e19268. [CrossRef]
19. Jeong, S.; Kim, S.H.; Hwang, E.J.; Shin, C.; Han, J.K.; Choi, B.I. Usefulness of a Metal Artifact Reduction Algorithm for Orthopedic Implants in Abdominal CT: Phantom and Clinical Study Results. *Am. J. Roentgenol.* **2015**, *204*, 307–317. [CrossRef]
20. Kohyama, S.; Yoshii, Y.; Okamoto, Y.; Nakajima, T. Advances in Bone Joint Imaging-Metal Artifact Reduction. *Diagnostics* **2022**, *12*, 3079. [CrossRef]
21. Midthun, P.; Kirkhus, E.; Østerås, B.H.; Høiness, P.R.; England, A.; Johansen, S. Metal Artifact Reduction on Musculoskeletal CT: A Phantom and Clinical Study. *Eur. Radiol. Exp.* **2023**, *7*, 46. [CrossRef]
22. Shim, E.; Kang, Y.; Ahn, J.M.; Lee, E.; Lee, J.W.; Oh, J.H.; Kang, H.S. Metal Artifact Reduction for Orthopedic Implants (O-MAR): Usefulness in CT Evaluation of Reverse Total Shoulder Arthroplasty. *Am. J. Roentgenol.* **2017**, *209*, 860–866. [CrossRef] [PubMed]

23. Naraghi, A.M.; White, L.M. Magnetic Resonance Imaging of Joint Replacements. *Semin. Musculoskelet. Radiol.* **2006**, *10*, 098–106. [CrossRef] [PubMed]
24. Koch, K.M.; Brau, A.C.; Chen, W.; Gold, G.E.; Hargreaves, B.A.; Koff, M.; McKinnon, G.C.; Potter, H.G.; King, K.F. Imaging near Metal with a MAVRIC-SEMAC Hybrid. *Magn. Reson. Med.* **2011**, *65*, 71–82. [CrossRef]
25. Hayter, C.L.; Koff, M.F.; Shah, P.; Koch, K.M.; Miller, T.T.; Potter, H.G. MRI After Arthroplasty: Comparison of MAVRIC and Conventional Fast Spin-Echo Techniques. *Am. J. Roentgenol.* **2011**, *197*, W405–W411. [CrossRef]
26. Choi, S.-J.; Koch, K.M.; Hargreaves, B.A.; Stevens, K.J.; Gold, G.E. Metal Artifact Reduction with MAVRIC SL at 3-T MRI in Patients with Hip Arthroplasty. *Am. J. Roentgenol.* **2015**, *204*, 140–147. [CrossRef]
27. Sutter, R.; Hodek, R.; Fucentese, S.F.; Nittka, M.; Pfirrmann, C.W.A. Total Knee Arthroplasty MRI Featuring Slice-Encoding for Metal Artifact Correction: Reduction of Artifacts for STIR and Proton Density–Weighted Sequences. *Am. J. Roentgenol.* **2013**, *201*, 1315–1324. [CrossRef]
28. Khodarahmi, I.; Khanuja, H.S.; Stern, S.E.; Carrino, J.A.; Fritz, J. Compressed Sensing SEMAC MRI of Hip, Knee, and Ankle Arthroplasty Implants: A 1.5-T and 3-T Intrapatient Performance Comparison for Diagnosing Periprosthetic Abnormalities. *Am. J. Roentgenol.* **2023**, *221*, 661–672. [CrossRef]
29. Niccoli, G.; Mercurio, D.; Cortese, F. Bone Scan in Painful Knee Arthroplasty: Obsolete or Actual Examination? *Acta Biomed. Atenei Parm.* **2017**, *88*, 68.
30. Claassen, L.; Ettinger, M.; Plaass, C.; Daniilidis, K.; Calliess, T.; Ezechieli, M. Diagnostic Value of Bone Scintigraphy for Aseptic Loosening after Total Knee Arthroplasty. *THC* **2014**, *22*, 767–773. [CrossRef] [PubMed]
31. Verberne, S.J.; Kuiper, J.W.P.; Broos, W.A.M.; Temmerman, O.P.P. Systematic Review on Reproducibility of Nuclear Imaging in the Assessment of Painful Hip and Knee Replacements. *SN Compr. Clin. Med.* **2020**, *2*, 1491–1504. [CrossRef]
32. Boero, M.; Allocca, M.; Pisu, N.; Sanna, S.; Ruggiero, A.; Pung, B.L.J.; Margotti, S.; Dessì, G. Management of Periprosthetic Knee Joint Infections: Focus on the Role of Nuclear Medicine (V2). *Orthop. Rev.* **2022**, *14*, 39646. [CrossRef] [PubMed]
33. Palestro, C.J. Nuclear Medicine and the Failed Joint Replacement: Past, Present, and Future. *WJR* **2014**, *6*, 446. [CrossRef] [PubMed]
34. Izakovicova, P.; Borens, O.; Trampuz, A. Periprosthetic Joint Infection: Current Concepts and Outlook. *EFORT Open Rev.* **2019**, *4*, 482–494. [CrossRef]
35. Palestro, C.J.; Swyer, A.J.; Kim, C.K.; Goldsmith, S.J. Infected Knee Prosthesis: Diagnosis with In-111 Leukocyte, Tc-99m Sulfur Colloid, and Tc-99m MDP Imaging. *Radiology* **1991**, *179*, 645–648. [CrossRef]
36. Verberne, S.J.; Sonnega, R.J.A.; Temmerman, O.P.P.; Raijmakers, P.G. What Is the Accuracy of Nuclear Imaging in the Assessment of Periprosthetic Knee Infection? A Meta-Analysis. *Clin. Orthop. Relat. Res.* **2017**, *475*, 1395–1410. [CrossRef]
37. Hirschmann, M.T.; Amsler, F.; Rasch, H. Clinical Value of SPECT/CT in the Painful Total Knee Arthroplasty (TKA): A Prospective Study in a Consecutive Series of 100 TKA. *Eur. J. Nucl. Med. Mol. Imaging* **2015**, *42*, 1869–1882. [CrossRef]
38. Peng, Z.; Jia, Y.; Li, J.; Wang, G. Diagnostic Performance of Single-Photon Emission Computed Tomography/Computed Tomography in Aseptic Loosening: A Systematic Review and Meta-Analysis. *J. Arthroplast.* **2021**, *36*, 4003–4012.e3. [CrossRef]
39. Murer, A.M.; Hirschmann, M.T.; Amsler, F.; Rasch, H.; Huegli, R.W. Bone SPECT/CT Has Excellent Sensitivity and Specificity for Diagnosis of Loosening and Patellofemoral Problems after Total Knee Arthroplasty. *Knee Surg. Sports Traumatol. Arthrosc.* **2020**, *28*, 1029–1035. [CrossRef] [PubMed]
40. Bao, B.; Liu, C.; Masson, E.C.O.; Abele, J. Diagnostic Accuracy of SPECT/CT Arthrography in Patients with Suspected Aseptic Joint Prosthesis Loosening 2020. *Eur. J. Hybrid Imaging* **2021**, *5*, 4. [CrossRef]
41. Chew, C.G.; Lewis, P.; Middleton, F.; Van Den Wijngaard, R.; Deshaies, A. Radionuclide Arthrogram with SPECT/CT for the Evaluation of Mechanical Loosening of Hip and Knee Prostheses. *Ann. Nucl. Med.* **2010**, *24*, 735–743. [CrossRef]
42. Hoveidaei, A.; Tavakoli, Y.; Ramezanpour, M.R.; Omouri-kharashtomi, M.; Taghavi, S.P.; Hoveidaei, A.H.; Conway, J.D. Imaging in Periprosthetic Joint Infection Diagnosis: A Comprehensive Review. *Microorganisms* **2024**, *13*, 10. [CrossRef] [PubMed]
43. Mokoala, K.M.G.; Ndlovu, H.; Lawal, I.; Sathekge, M.M. PET/CT and SPECT/CT for Infection in Joints and Bones: An Overview and Future Directions. *Semin. Nucl. Med.* **2024**, *54*, 394–408. [CrossRef]
44. Koob, S.; Gaertner, F.C.; Jansen, T.R.; Schmolders, J.; Gravius, S.; Strunk, H.; Wirtz, D.C.; Essler, M. Diagnosis of Peri-Prosthetic Loosening of Total Hip and Knee Arthroplasty Using 18F-Fluoride PET/CT. *Oncotarget* **2019**, *10*, 2203–2211. [CrossRef]
45. Röhner, E.; Heinecke, M.; Matziolis, G. Diagnostic Algorithm in Aseptic TKA Failure—What Is Evidence-Based? *J. Orthop.* **2021**, *24*, 248–253. [CrossRef]
46. Van Den Wyngaert, T.; Palli, S.R.; Imhoff, R.J.; Hirschmann, M.T. Cost-Effectiveness of Bone SPECT/CT in Painful Total Knee Arthroplasty. *J. Nucl. Med.* **2018**, *59*, 1742–1750. [CrossRef] [PubMed]
47. Love, C.; Marwin, S.E.; Palestro, C.J. Nuclear Medicine and the Infected Joint Replacement. *Semin. Nucl. Med.* **2009**, *39*, 66–78. [CrossRef] [PubMed]
48. Al-Jabri, T.; Ridha, M.; Wood, M.J.; Kayani, B.; Jayadev, C.; McCulloch, R.A.; Schemitsch, E. An Overview of the Current Diagnostic Approach to Periprosthetic Joint Infections. *Orthop. Rev.* **2024**, *16*, 120308. [CrossRef]

49. Puijk, R.; Lubbe, P.; Sierevelt, I.N.; Kristians, A.E.; Boer, J.; Nolte, P.A. The Diagnostic Characteristic and Reproducibility of Bone Scintigraphy Single-Photon Emission Computed Tomography/Computed Tomography for Diagnosing Aseptic Loosening of Uncemented Total Knee Arthroplasty. *J. Arthroplast.* **2024**, *39*, 1707–1713.e1. [CrossRef]
50. Anzola, L.K.; Hernandez, N.; Rodriguez, L.F.; Sanguino, G.; Martinez, E.; Lopez, R.; Moreno, S.; Prill, R.; Mut, F.; Rasch, H.; et al. The Role of SPECT/CT in Painful, Noninfected Knees after Knee Arthroplasty: A Systematic Review and Meta-Analysis—A Diagnostic Test Accuracy Review. *J. Orthop. Surg. Res.* **2023**, *18*, 223. [CrossRef]
51. Tian, Y.; Jiang, Y.; Feng, B.; Zhao, T.; Cai, W.; Dong, Y.; Zhao, Q. Can99mTc-MDP–SPECT/CT Differentiate Loosening and Infection After Hip and Knee Replacements? *JOIO* **2024**, *58*, 316–322. [CrossRef]
52. Talebi, S.; Rahmani, E.; Abdinejad, M.; Ahmadzade, M.; Hoorshad, B.; Fard, A.M.; Fard, T.M.; Shafigh, A.; Momeni, H.; Radpour, N.; et al. Diagnostic Performance of SPECT/CT for Identification of Aseptic Loosening after Total Knee and Hip Arthroplasty: A Systematic Review and Meta-Analysis. *Acta Orthop. Belg.* **2024**, *90*, 503–511. [CrossRef]
53. Hu, M.; Chen, G.; Luo, L.; Shang, L. A Systematic Review and Meta-Analysis on the Accuracy of Fluorodeoxyglucose Positron Emission Tomography/Computerized Tomography for Diagnosing Periprosthetic Joint Infections. *Front. Surg.* **2022**, *9*, 698781. [CrossRef]
54. Kim, S.-J.; Cho, Y.J. Current Guideline for Diagnosis of Periprosthetic Joint Infection: A Review Article. *Hip Pelvis* **2021**, *33*, 11–17. [CrossRef]
55. Parvizi, J.; Tan, T.L.; Goswami, K.; Higuera, C.; Della Valle, C.; Chen, A.F.; Shohat, N. The 2018 Definition of Periprosthetic Hip and Knee Infection: An Evidence-Based and Validated Criteria. *J. Arthroplast.* **2018**, *33*, 1309–1314.e2. [CrossRef]
56. Tsikopoulos, K.; Meroni, G. Periprosthetic Joint Infection Diagnosis: A Narrative Review. *Antibiotics* **2023**, *12*, 1485. [CrossRef]
57. McNally, M.; Sousa, R.; Wouthuyzen-Bakker, M.; Chen, A.F.; Soriano, A.; Vogely, H.C.; Clauss, M.; Higuera, C.A.; Trebše, R. The EBJIS Definition of Periprosthetic Joint Infection: A Practical Guide for Clinicians. *Bone Jt. J.* **2021**, *103-B*, 18–25. [CrossRef] [PubMed]
58. Xie, K.; Dai, K.; Qu, X.; Yan, M. Serum and Synovial Fluid Interleukin-6 for the Diagnosis of Periprosthetic Joint Infection. *Sci. Rep.* **2017**, *7*, 1496. [CrossRef] [PubMed]
59. Li, J.; Zhou, Q.; Deng, B. Serum versus Synovial Fluid Interleukin-6 for Periprosthetic Joint Infection Diagnosis: A Systematic Review and Meta-Analysis of 30 Diagnostic Test Accuracy Studies. *J. Orthop. Surg. Res.* **2022**, *17*, 564. [CrossRef]
60. Li, C.; Li, H.; Yang, X.; Zhu, F.-Z.; Xu, C.; Trampuz, A. Meta-Analysis of Synovial Fluid Polymerase Chain Reaction for Diagnosing Periprosthetic Hip and Knee Infection. *J. Orthop. Surg. Res.* **2022**, *17*, 3. [CrossRef] [PubMed]
61. Esteban, J.; Salar-Vidal, L.; Schmitt, B.H.; Waggoner, A.; Laurent, F.; Abad, L.; Bauer, T.W.; Mazariegos, I.; Balada-Llasat, J.-M.; Horn, J.; et al. Multicenter Evaluation of the BIOFIRE Joint Infection Panel for the Detection of Bacteria, Yeast, and AMR Genes in Synovial Fluid Samples. *J. Clin. Microbiol.* **2023**, *61*, e00357-23. [CrossRef]
62. Bonanzinga, T.; Ferrari, M.C.; Tanzi, P.; Vandenbulcke, F.; Zahar, A.; Marcacci, M. The Role of Alpha Defensin in Prosthetic Joint Infection (PJI) Diagnosis: A Literature Review. *EFORT Open Rev.* **2019**, *4*, 10–13. [CrossRef]
63. Trampuz, A.; Piper, K.E.; Jacobson, M.J.; Hanssen, A.D.; Unni, K.K.; Osmon, D.R.; Mandrekar, J.N.; Cockerill, F.R.; Steckelberg, J.M.; Greenleaf, J.F.; et al. Sonication of Removed Hip and Knee Prostheses for Diagnosis of Infection. *N. Engl. J. Med.* **2007**, *357*, 654–663. [CrossRef]
64. Araújo, D.; Martins, J.P.; Ferreira, S.L.; Mota, S.; Ferreira, P.L.; Pimenta, R. A Meta-Analysis on the Role of Sonication in the Diagnosis of Cardiac Implantable Electronic Device-Related Infections. *Front. Microbiol.* **2024**, *15*, 1361626. [CrossRef] [PubMed]
65. Alvarez Otero, J.; Karau, M.J.; Greenwood-Quaintance, K.E.; Abdel, M.P.; Mandrekar, J.; Patel, R. Evaluation of Sonicate Fluid Culture Cutoff Points for Periprosthetic Joint Infection Diagnosis. *Open Forum Infect. Dis.* **2024**, *11*, ofae159. [CrossRef]
66. Silva, N.D.S.; De Melo, B.S.T.; Oliva, A.; De Araújo, P.S.R. Sonication Protocols and Their Contributions to the Microbiological Diagnosis of Implant-Associated Infections: A Review of the Current Scenario. *Front. Cell. Infect. Microbiol.* **2024**, *14*, 1398461. [CrossRef] [PubMed]
67. Mederake, M.; Hofmann, U.K.; Fink, B. The Significance of Synovial Biopsy in the Diagnostic Workup of the Low-Grade Periprosthetic Joint Infection of Shoulder Arthroplasty. *Arch. Orthop. Trauma. Surg.* **2021**, *142*, 3157–3164. [CrossRef] [PubMed]
68. Deirmengian, C.; Kardos, K.; Kilmartin, P.; Cameron, A.; Schiller, K.; Parvizi, J. Combined Measurement of Synovial Fluid α-Defensin and C-Reactive Protein Levels: Highly Accurate for Diagnosing Periprosthetic Joint Infection. *J. Bone Jt. Surg.* **2014**, *96*, 1439–1445. [CrossRef]
69. Beguiristain, I.; Henriquez, L.; Sancho, I.; Martin, C.; Hidalgo-Ovejero, A.; Ezpeleta, C.; Portillo, M.E. Direct Prosthetic Joint Infection Diagnosis from Sonication Fluid Inoculated in Blood Culture Bottles by Direct MALDI-TOF Mass Spectrometry. *Diagnostics* **2023**, *13*, 942. [CrossRef]
70. Ro, J.; Ro, D.H.; Kang, Y.; Han, H.-S.; Shin, C.S. Biomechanical Effect of Coronal Alignment and Ligament Laxity in Total Knee Arthroplasty: A Simulation Study. *Front. Bioeng. Biotechnol.* **2022**, *10*, 851495. [CrossRef]

71. Van Hamersveld, K.T.; Marang-van De Mheen, P.J.; Tsonaka, R.; Nilsson, K.G.; Toksvig-Larsen, S.; Nelissen, R.G.H.H. Risk Factors for Tibial Component Loosening: A Meta-Analysis of Long-Term Follow-up Radiostereometric Analysis Data. *J. Bone Jt. Surg.* **2021**, *103*, 1115–1124. [CrossRef]
72. Ten Brinke, B.; Beumer, A.; Koenraadt, K.L.M.; Eygendaal, D.; Kraan, G.A.; Mathijssen, N.M.C. The Accuracy and Precision of Radiostereometric Analysis in Upper Limb Arthroplasty: A Systematic Review of 23 RSA Studies. *Acta Orthop.* **2017**, *88*, 320–325. [CrossRef]
73. Marino, G.; De Capitani, F.; Adamo, P.; Bolzoni, L.; Gatti, R.; Temporiti, F. Long-Term Gait Analysis in Patients after Total Knee Arthroplasty: A Systematic Review and Meta-Analysis. *Gait Posture* **2024**, *113*, 75–98. [CrossRef]
74. Yu, X.; Zhuang, R.; Jin, P. Evaluation of the Efficacy after Total Knee Arthroplasty by Gait Analysis in Patients with Knee Osteoarthritis: A Meta-Analysis. *J. Orthop. Surg. Res.* **2024**, *19*, 612. [CrossRef] [PubMed]
75. Szczypiór-Piasecka, K.; Adamczewska, P.; Kołodziej, Ł.; Ziętek, P. The Temporal–Spatial Parameters of Gait After Total Knee Arthroplasty. *JCM* **2025**, *14*, 4548. [CrossRef] [PubMed]
76. Stentz-Olesen, K.; Nielsen, E.T.; De Raedt, S.; Jørgensen, P.B.; Sørensen, O.G.; Kaptein, B.L.; Andersen, M.S.; Stilling, M. Validation of Static and Dynamic Radiostereometric Analysis of the Knee Joint Using Bone Models from CT Data. *Bone Jt. Res.* **2017**, *6*, 376–384. [CrossRef]
77. Van De Vusse, S.F.; De Laat, N.N.; Koster, L.A.; Kaptein, B.L. The Accuracy and Precision of CT-RSA in Arthroplasty: A Systematic Review and Meta-Analysis. *Acta Orthop.* **2025**, *96*, 295–303. [CrossRef] [PubMed]
78. Salis, F.; Bertuletti, S.; Bonci, T.; Caruso, M.; Scott, K.; Alcock, L.; Buckley, E.; Gazit, E.; Hansen, C.; Schwickert, L.; et al. A Multi-Sensor Wearable System for the Assessment of Diseased Gait in Real-World Conditions. *Front. Bioeng. Biotechnol.* **2023**, *11*, 1143248. [CrossRef]
79. Feng, Y.; Liu, Y.; Fang, Y.; Chang, J.; Deng, F.; Liu, J.; Xiong, Y. Advances in the Application of Wearable Sensors for Gait Analysis after Total Knee Arthroplasty: A Systematic Review. *Arthroplasty* **2023**, *5*, 49. [CrossRef]
80. Giuntoli, M.; Scaglione, M.; Bonicoli, E.; Piolanti, N.; Puccioni, G.; Zepeda, K.; Giannini, E.; Marchetti, S.; Indelli, P.F. Intraoperative Load Sensing in Total Knee Arthroplasty Leads to a Functional but Not Clinical Difference: A Comparative, Gait Analysis Evaluation. *JFMK* **2022**, *7*, 23. [CrossRef]
81. Al-Nasser, S.; Noroozi, S.; Harvey, A.; Aslani, N.; Haratian, R. Exploring the Performance of an Artificial Intelligence-Based Load Sensor for Total Knee Replacements. *Sensors* **2024**, *24*, 585. [CrossRef]
82. Kubo, Y.; Fujita, D.; Sugiyama, S.; Takachu, R.; Sugiura, T.; Sawada, M.; Yamashita, K.; Kobori, K.; Kobori, M. Quadriceps Strength Loss Following Total Knee Arthroplasty as a Predictor of Three-Month Strength Recovery: A Secondary Analysis of a Randomized Controlled Trial. *Cureus* **2024**, *16*, e68244. [CrossRef]
83. Paravlic, A.H.; Meulenberg, C.J.; Drole, K. The Time Course of Quadriceps Strength Recovery After Total Knee Arthroplasty Is Influenced by Body Mass Index, Sex, and Age of Patients: Systematic Review and Meta-Analysis. *Front. Med.* **2022**, *9*, 865412. [CrossRef] [PubMed]
84. Puijk, R.; Singh, J.; Puijk, R.H.; Laende, E.K.; Plevier, J.W.M.; Nolte, P.A.; Pijls, B.G.C.W. Evaluation and Refinement of Thresholds for Early Migration of Total Knee Replacements as an Estimator of Late Aseptic Loosening: An Updated Systematic Review of RSA and Survival Studies. *Acta Orthop.* **2025**, *96*, 1–10. [CrossRef] [PubMed]
85. Mizner, R.L.; Petterson, S.C.; Snyder-Mackler, L. Quadriceps Strength and the Time Course of Functional Recovery After Total Knee Arthroplasty. *J. Orthop. Sports Phys. Ther.* **2005**, *35*, 424–436. [CrossRef] [PubMed]
86. Kaptein, B.L.; Pijls, B.; Koster, L.; Kärrholm, J.; Hull, M.; Niesen, A.; Heesterbeek, P.; Callary, S.; Teeter, M.; Gascoyne, T.; et al. Guideline for RSA and CT-RSA Implant Migration Measurements: An Update of Standardizations and Recommendations. *Acta Orthop.* **2024**, *95*, 256–267. [CrossRef]
87. Wang, J.; Zhu, R.; Xu, X.; Liu, S.; Li, Z.; Guo, C.; Tao, X.; Qian, L.; Charles, R.; Fang, L. Effects of Strength Training on Functional Ambulation Following Knee Replacement: A Systematic Review, Meta-Analysis, and Meta-Regression. *Sci. Rep.* **2023**, *13*, 10728. [CrossRef]
88. Hiyama, Y.; Asai, T.; Wada, O. Effect of Improvement in Quadriceps Strength Asymmetry on Trunk Movement Asymmetry after Total Knee Arthroplasty. *Gait Posture* **2020**, *79*, 21–25. [CrossRef]
89. Karpiński, R.; Syta, A. Application of encoder-based motion analysis and machine learning for knee osteoarthritis detection: A pilot study. *Appl. Comput. Sci.* **2025**, *21*, 21–31. [CrossRef]
90. Khokhlova, L.; Komaris, D.-S.; Tedesco, S.; O'Flynn, B. Assessment of Hip and Knee Joints and Implants Using Acoustic Emission Monitoring: A Scoping Review. *IEEE Sens. J.* **2021**, *21*, 14379–14388. [CrossRef]
91. Karpiński, R.; Prus, A.; Jonak, K.; Krakowski, P. Vibroarthrography as a Noninvasive Screening Method for Early Diagnosis of Knee Osteoarthritis: A Review of Current Research. *Appl. Sci.* **2024**, *15*, 279. [CrossRef]
92. Krishnan, S.; Rangayyan, R.M.; Bell, G.D.; Frank, C.B. Adaptive Time-Frequency Analysis of Knee Joint Vibroarthrographic Signals for Noninvasive Screening of Articular Cartilage Pathology. *IEEE Trans. Biomed. Eng.* **2000**, *47*, 773–783. [CrossRef]

93. Machrowska, A.; Karpiński, R.; Maciejewski, M.; Jonak, J.; Krakowski, P.; Syta, A. Hybrid Framework for Cartilage Damage Detection from Vibroacoustic Signals Using Ensemble Empirical Mode Decomposition and CNNs. *Sensors* **2025**, *25*, 6638. [CrossRef]
94. Kienapfel, H.; Sprey, C.; Wilke, A.; Griss, P. Implant Fixation by Bone Ingrowth. *J. Arthroplast.* **1999**, *14*, 355–368. [CrossRef] [PubMed]
95. Schwabe, M.T.; Hannon, C.P. The Evolution, Current Indications and Outcomes of Cementless Total Knee Arthroplasty. *JCM* **2022**, *11*, 6608. [CrossRef]
96. Gao, X.; Fraulob, M.; Haïat, G. Biomechanical Behaviours of the Bone-Implant Interface: A Review. *J. R. Soc. Interface* **2019**, *16*, 20190259. [CrossRef] [PubMed]
97. Whittingslow, D.C.; Zia, J.; Gharehbaghi, S.; Gergely, T.; Ponder, L.A.; Prahalad, S.; Inan, O.T. Knee Acoustic Emissions as a Digital Biomarker of Disease Status in Juvenile Idiopathic Arthritis. *Front. Digit. Health* **2020**, *2*, 571839. [CrossRef]
98. Glaser, D.; Komistek, R.D.; Cates, H.E.; Mahfouz, M.R. A Non-Invasive Acoustic and Vibration Analysis Technique for Evaluation of Hip Joint Conditions. *J. Biomech.* **2010**, *43*, 426–432. [CrossRef]
99. Georgiou, A.P.; Cunningham, J.L. Accurate Diagnosis of Hip Prosthesis Loosening Using a Vibrational Technique. *Clin. Biomech.* **2001**, *16*, 315–323. [CrossRef]
100. Leuridan, S.; Goossens, Q.; Vander Sloten, T.; De Landsheer, K.; Delport, H.; Pastrav, L.; Denis, K.; Desmet, W.; Vander Sloten, J. Vibration-Based Fixation Assessment of Tibial Knee Implants: A Combined in Vitro and in Silico Feasibility Study. *Med. Eng. Phys.* **2017**, *49*, 109–120. [CrossRef]
101. Zhou, Q.; Rose, L.R.F.; Ebeling, P.; Russ, M.; Fitzgerald, M.; Chiu, W.K. Harmonic Vibration Analysis in a Simplified Model for Monitoring Transfemoral Implant Loosening. *Sensors* **2024**, *24*, 6453. [CrossRef]
102. Karpiński, R.; Prus, A.; Baj, J.; Radej, S.; Prządka, M.; Krakowski, P.; Jonak, K. Articular Cartilage: Structure, Biomechanics, and the Potential of Conventional and Advanced Diagnostics. *Appl. Sci.* **2025**, *15*, 6896. [CrossRef]
103. Kalo, K.; Niederer, D.; Sus, R.; Sohrabi, K.; Groß, V.; Vogt, L. Reliability of Vibroarthrography to Assess Knee Joint Sounds in Motion. *Sensors* **2020**, *20*, 1998. [CrossRef] [PubMed]
104. Tenberg, S.; Kalo, K.; Niederer, D.; Vogt, L. Effect of Warm-up and Muscle Fatiguing Exercise on Knee Joint Sounds in Motion by Vibroarthrography: A Randomized Crossover Trial. *PLoS ONE* **2021**, *16*, e0257652. [CrossRef]
105. Łysiak, A.; Froń, A.; Bączkowicz, D.; Szmajda, M. Vibroarthrographic Signal Spectral Features in 5-Class Knee Joint Classification. *Sensors* **2020**, *20*, 5015. [CrossRef]
106. Kręcisz, K.; Bączkowicz, D.; Kawala-Sterniuk, A. Using Nonlinear Vibroartrographic Parameters for Age-Related Changes Assessment in Knee Arthrokinematics. *Sensors* **2022**, *22*, 5549. [CrossRef] [PubMed]
107. Barnsley, L.; Barnsley, L. Detection of Aseptic Loosening in Total Knee Replacements: A Systematic Review and Meta-Analysis. *Skelet. Radiol.* **2019**, *48*, 1565–1572. [CrossRef]
108. Park, C.; Lee, S.-M.; Seo, J.S.; Kim, T.W.; Rhee, S.J.; Jeong, H.S. Metal Artifact Reduction Dual-Energy CT as an Accurate and Reliable Method for Measuring Total Knee Arthroplasty Femoral Component Rotation Compared to Conventional CT. *J. Knee Surg.* **2023**, *36*, 988–994. [CrossRef]
109. Zhang, J.; Wang, X.; Zhao, F.; Zhang, K.; Li, Y.; Zhang, Y.; Zeng, Y.; Xia, C.; Li, Z. Application of Metal Artifact Reduction Software in Gemstone Spectral Computed Tomography for Patients after Total Knee Arthroplasty. *Ann. Transl. Med.* **2022**, *10*, 864. [CrossRef]
110. Endo, Y.; Burge, A.J.; Koff, M.F.; Lin, B.; Westrich, G.H.; Boettner, F.; Chiu, Y.-F.; Potter, H.G. Diagnostic Performance of MRI for Component Loosening in Total Knee Arthroplasty Compared with Radiography. *Radiology* **2022**, *304*, 128–136. [CrossRef]
111. Fritz, J.; Lurie, B.; Potter, H.G. MR Imaging of Knee Arthroplasty Implants. *RadioGraphics* **2015**, *35*, 1483–1501. [CrossRef] [PubMed]
112. Quinlan, N.D.; Jennings, J.M. Joint Aspiration for Diagnosis of Chronic Periprosthetic Joint Infection: When, How, and What Tests? *Arthroplasty* **2023**, *5*, 43. [CrossRef] [PubMed]

Disclaimer/Publisher's Note: The statements, opinions and data contained in all publications are solely those of the individual author(s) and contributor(s) and not of MDPI and/or the editor(s). MDPI and/or the editor(s) disclaim responsibility for any injury to people or property resulting from any ideas, methods, instructions or products referred to in the content.